

## RECURRENT OVARIAN CARCINOMA



**North Florida Regional CyberKnife® Team:**

Radiation Oncologists: Mark Perman, M.D.  
Cheryle A. Hayes, M.D.

Gynecologist: Kelli C. Ross, M.D.

Chief Medical Physicist: Donald Dubois, Ph.D.

Medical Physicist: Howard Salmon, Ph.D.

Medical Dosimetrist: Eric Larsen, CMD, RTT

CyberKnife Therapists: Jeanne Wilson, RTT  
Scott McGee, RTT

Director of  
North Florida Radiation  
Oncology Center: Gail Suarez, MSHSA, RT(R)(T)

CyberKnife Center: North Florida Regional Medical Center  
Gainesville, FL

## RECURRENT OVARIAN CANCER

### DEMOGRAPHICS

**Sex:** Female  
**Age:** 60 years  
**Histology:** Poorly differentiated serous papillary ovarian carcinoma

### CLINICAL HISTORY

**Referred by:** Gynecologist  
**Past Medical History:** Stage IV ovarian carcinoma

### Case History

A 60-year-old female with a history of Stage IV ovarian carcinoma presented with rising CA-125 levels (21.1 U/ml to 34.4 U/ml), signifying a probable ovarian carcinoma recurrence. Subsequent MRI showed a 2.8 x 2.5 cm nodule in the region of the left upper vaginal cuff which was confirmed by bimanual examination.

Initial diagnosis of Stage IV ovarian carcinoma was made six years earlier when the patient presented with right-sided pleural effusion and CA-125 of 1482 U/ml. An exploratory laparotomy was done and an omental cake, peritoneal studding and a nodule adjacent to the rectosigmoid were resected. Pathology showed poorly differentiated serous papillary ovarian carcinoma. Over the next four years the patient underwent multiple rounds of chemotherapy as well as stem cell transplant and additional surgical resection in the effort to control her disease. The patient's latest chemotherapy was prematurely discontinued when she experienced a severe anaphylactoid reaction. At that time the decision was made to follow her closely with imaging and CA-125 measurements.

### CyberKnife® Treatment Rationale

Epithelial ovarian cancer is the leading cause of death among women with gynecologic malignancies and is the fifth most common cancer in women in the US. More than 70% of women with epithelial ovarian cancer have Stage III or IV disease at the time of diagnosis.<sup>1</sup> Adjuvant chemotherapy is recommended for all patients with advanced stage ovarian cancer after appropriate surgery. However, more than 70% of patients relapse, with a median time to progression of less than 2 years.<sup>2</sup> Secondary surgery for recurrent patients has not significantly improved survival. Radiation therapy has improved survival in a subset of patients with chemotherapy-refractory disease, particularly those patients with minimal residual or relapsed disease to the pelvis, and has provided good palliation in patients with local abdominopelvic symptoms.<sup>3</sup> This patient presented with a recurrent ovarian cancer in the left vaginal cuff. Due to the patient's medical history, she was not a candidate for further chemotherapy or surgery. Nevertheless, the left vaginal cuff recurrence was and has always been the only site of recurrence in this patient, therefore aggressive definitive care was indicated. High dose rate brachytherapy was considered, but was declined due to its invasive nature with the attendant risks of surgery. External beam radiation was considered an inferior option due to the inability to limit the dose to adjacent critical structures with increased risks of bladder, vaginal and rectal toxicities. The use of stereotactic body radiotherapy as an alternative to brachytherapy for gynecologic tumors has been reported and shown to achieve excellent local control rates with minimal toxicities.<sup>4</sup> The CyberKnife® Radiosurgery System offered a minimally invasive method for delivering hypofractionated radiation to the left vaginal cuff of a patient who had failed two surgical resections and numerous cycles of chemotherapy.

**TREATMENT DETAILS**

**Treatment Volume:** 42.53 cc  
**Imaging Technique(s):** CT  
**Rx Dose & Isodose:** 30 Gy to 69%  
**Dose and Fractions:** 10 Gy x 3 fractions  
**Number of Beams:** 114  
**Number of Fiducials:** 4

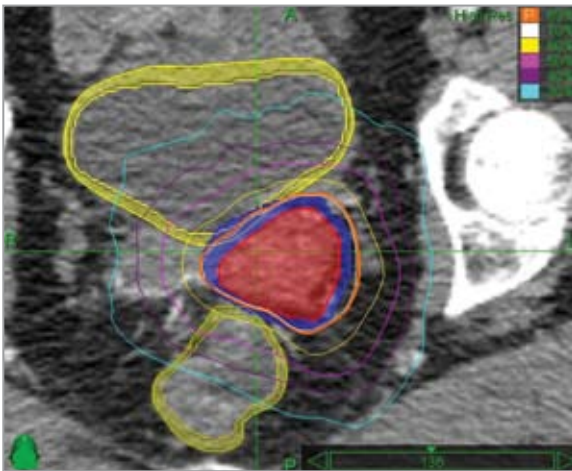
**Number of Nodes:** 140  
**Treatment Time:** 33-36 minutes/fraction  
**Conformality Index:** 1.25  
**Tracking Method:** Fiducial  
**Collimator(s):** 35 mm  
**Tumor Coverage:** 94.9%

**Planning Process**

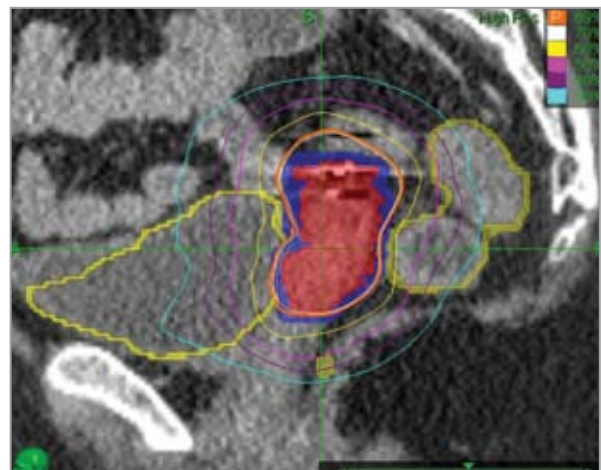
The patient was prepared for treatment planning by implanting four fiducials into the periphery of the tumor by the gynecologist. A planning CT scan was obtained 7 days later. The fiducials were identified and the lesion was outlined on the scans. The GTV was defined as the tumor and the PTV was defined as the GTV plus a 3-mm expansion resulting in a treatment volume of 42.53 cc. The final plan was created to deliver 30 Gy in 3 fractions to the 69% isodose line. The patient began treatment 6 days after the planning CT images were taken.

**Treatment Delivery**

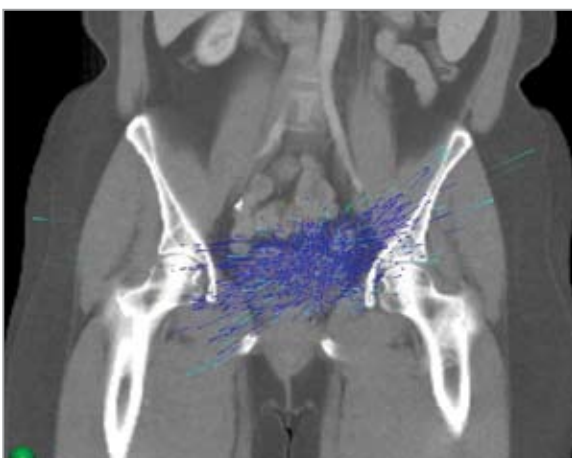The patient received 30 Gy delivered in three fractions over four days. The treatment was delivered to a volume of 42.53 cc using 114 beams and a 35-mm collimator. The 69% isodose line provided 94.9% coverage of the PTV, with a conformality index of 1.25. The maximum rectal dose was 30.33 Gy. Less than 0.22 cc of the rectum received greater than 28.8 Gy, meeting the rectal constraint of less than 1 cc of the rectum receiving that dose. The maximum bladder dose was 31.8 Gy with less than 0.47 cc of the bladder receiving greater than 30 Gy. The bladder constraint of less than 10 cc of the bladder receiving greater than 30 Gy was easily met.



Axial treatment plan showing isodose curves to the tumor while sparing the rectum and bladder (outlined in yellow). The orange line indicates the prescription dose to the 69% isodose line providing 94.9% coverage of the PTV.



Sagittal view of the treatment plan showing isodose curves to the tumor while sparing the rectum and bladder (outlined in yellow). The orange line indicates the prescription dose to the 69% isodose line.



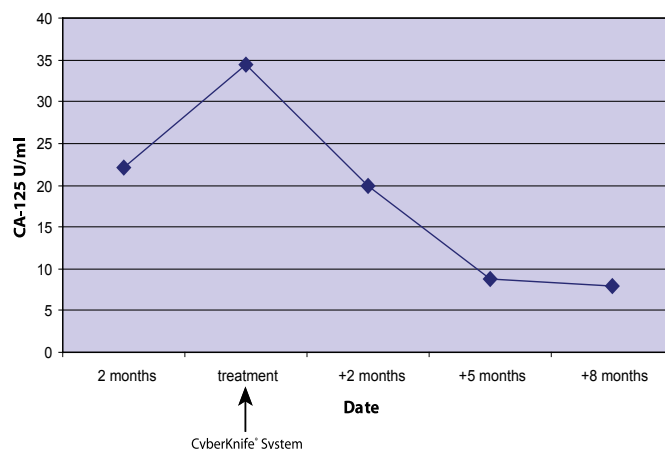
3D image of the bony anatomy and CyberKnife beam positions delivered to the left vaginal cuff.

## RECURRENT OVARIAN CANCER

### Outcome and Follow-Up

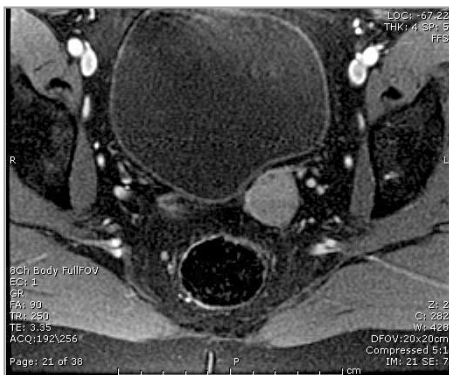
- One month following the CyberKnife® treatment a CT scan demonstrated a decrease in size of the left vaginal cuff lesion, which measured 1.86 x 2.14 cm.
- Eight months after the CyberKnife treatment the mass could not be seen on CT imaging and only minimal fullness in the left vaginal wall could be detected on CT imaging.
- The patient experienced minimal toxicities following CyberKnife treatment, which included occasional loose stools and mild vaginal discharge that resolved six weeks post-treatment without medications, as well as mild urinary urgency and fatigue which completely resolved by five months post-treatment without medications.
- Eight months after CyberKnife treatment, CA-125 levels decreased to 7.9 U/ml.

CA-125 levels obtained prior to and following CyberKnife treatment

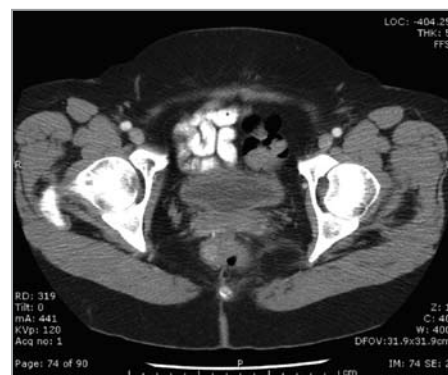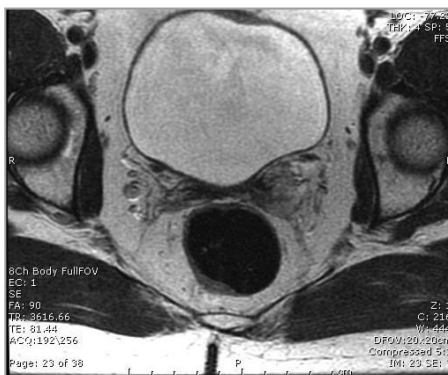


### Conclusion and CyberKnife® Advantages

- This patient had an excellent initial outcome with the CyberKnife System for the treatment of a recurrent ovarian carcinoma located at the vaginal cuff.
- The CyberKnife System delivered hypofractionated radiosurgery to the vaginal cuff with minimal toxicities to the bladder and rectum.
- The CyberKnife System provided a convenient and minimally invasive treatment option for this patient with recurrent ovarian carcinoma who had failed previous surgery and chemotherapy.
- A benefit of the CyberKnife System's capacity to target lesions precisely is the potential for low toxicity to critical nearby organs such as the bladder, rectum, urethra, and vagina.



MRI images of 28 x 25 mm recurrent ovarian mass located at the left vaginal cuff prior to CyberKnife treatment.



CT image demonstrating no evidence of a left vaginal cuff mass or recurrence 8 months after CyberKnife treatment.

### NORTH FLORIDA REGIONAL MEDICAL CENTER

The CyberKnife Center at North Florida Radiation Oncology opened its doors on August 1, 2006 and treated more than 160 patients in its first year. The cases consist of 71% extracranial, 23% intracranial and 6% spinal treatments. HCA and North Florida Regional Medical Center, a 325-bed community hospital, are working together to develop a comprehensive cancer community oncology program to provide patients with quality care supported by state of the art technologies such as the CyberKnife.

Contact the CyberKnife Center at North Florida Radiation Oncology at 1-800-621-0575 or 352-333-5643.

### References

1. Jemal A, Siegel R, Ward E, et al. Cancer Statistics, 2006. CA Cancer J Clin 56: 106-130, 2006.
2. McGuire WP, Hoskins WJ, Brady MF et al. N Engl J Med 334: 1-6, 1996.
3. Fein DA, Morgan LS, Marcus RB et al. Int J Rad Oncol Biol Phys 29: 169-176, 1994.
4. Molla M, Escude L, Nouet P, et al. Int J Rad Oncol Biol Phys 62: 118-124, 2005.

